

A 55-year-old woman underwent two consecutive metastasectomy within four months due to left pulmonary metastases originated from a uterin leiomyosarcoma. Two months after the last operation she presented with a soft and lobulated mass just below her thoracotomy scar (Figure 1A, B). Chest x-ray revealed subcutaneous air densities considered as a colon herniated through the 5th intercostal space and elevated diaphragm (Figure 1C, D).

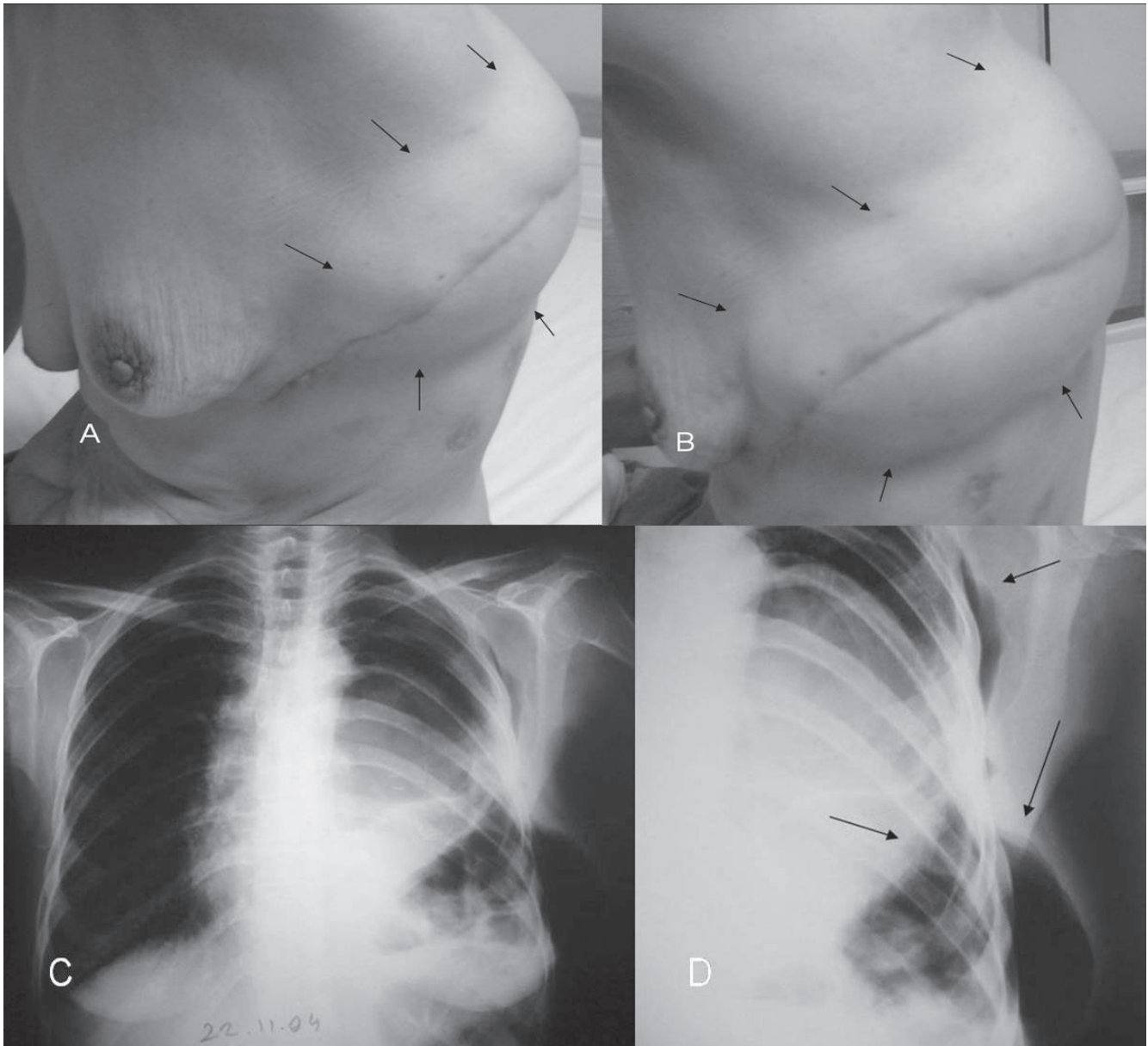


Figure 1. A soft and lobulated mass on the left thoracotomy incision scar detected on admission (A, B). Chest-X ray shows an opacity at left hilus (probably recurrences of metastatic leiomyosarcoma) associated with elevated diaphragm and subcutaneous air densities in consistent with herniated colon (arrows) (C, D).